

Familial Occurrence of α_1 -Antitrypsin Deficiency and Weber-Christian Disease

Samuel N. Breit, MB, BS, FRACP, FRCPA; Peggy Clark, PhD; J. Paul Robinson, MSc; Elizabeth Luckhurst; Roger L. Dawkins, MB, BS, BSc(Med), MD, MRCP, FRACP, FRCPA; Ronald Penny, DSc, MD, BS, FRACP, FRCPA

• Severe panniculitis of the Weber-Christian type occurred in two brothers, both with marked α_1 -antitrypsin (α_1 -AT) deficiency and phenotype PiZZ. Studies of inflammatory and immunologic function were undertaken in these two patients as well as in a third brother with severe α_1 -AT deficiency but without Weber-Christian disease. The findings of these investigations were suggestive of exaggerated immunologic and inflammatory function with enhanced lymphocyte responsiveness to phytohemagglutinin, enhanced activation of neutrophils and monocytes, and accelerated delayed hypersensitivity responses in all three subjects. This hyperreactivity may explain the apparent association of α_1 -AT deficiency with Weber-Christian disease.

(*Arch Dermatol* 1983;119:198-202)

Severe α_1 -antitrypsin (α_1 -AT) deficiency has been traditionally associated with emphysema and chronic liver disease. Recently, it has become apparent that various grades of deficiency are associated with a number of inflammatory and immunologic disorders such as rheumatoid arthritis,^{1,2} systemic lupus erythematosus,³ juvenile chronic polyarthritis,⁴ asthma,⁵ fibrosing alveolitis,⁶ and anterior uveitis.^{3,7} We report herein the occurrence of panniculitis of the Weber-Christian type in two brothers with severe α_1 -AT deficiency (phenotype PiZZ) and studies to elucidate some of the mechanisms that may be responsible for such an association.

REPORT OF CASES

CASE 1.—In October 1975, a 29-year-old man was seen because of a raised tender erythematous lesion in his left groin. History revealed that similar lesions had appeared recurrently on his trunk and extremities since childhood. These lesions were often precipitated by trauma. In October 1974, however, they had begun appearing more frequently; there were usually several at a time and they developed without a history of previous injury. The lesion in his left groin had gradually enlarged and spread to the left flank and genital region. He was therefore admitted to St Vincent's Hospital, Sydney, Australia, in December 1975. On admission he was noted to have raised erythematous indurated lesions, in the aforementioned sites, predominantly involving subcutaneous tissue. The rest of the findings from his physical examination were normal.

Shortly after admission to the hospital, the lesions became progressively more indurated and edematous, and

then ruptured, discharging a yellowish serous material from the groin and penis (Figure, left).

Cultures of the serous discharge and subsequent biopsy specimens were negative for fungi, bacteria, and viruses. The amylase content of the drainage fluid was also normal. Findings for complete blood cell count, ESR, serum urea nitrogen, creatinine, serum electrolytes, albumin, total protein, liver function tests, urinalysis, quantitative immunoglobulin and complement levels, and chest roentgenogram were all normal. No antinuclear antibodies, cryoproteins, or immune complexes were detected and serum electrophoresis was normal with the exception of low α_1 -globulin. Subsequently, the α_1 -AT level was found to be 0.2 g/L (normal, 2 to 4 g/L) and phenotyping, using isoelectric focusing, demonstrated phenotype PiZZ. Exploratory laparotomy was undertaken to exclude a perinephric abscess. This revealed densely indurated subcutaneous fat with gross edema of all layers from the subcutaneous tissue to perinephric fat; skin changes included a severe panniculitis with deep dermal venulitis and dermal subcutaneous histiocytic fibroblastic proliferation. The microscopic findings were believed to be that of a panniculitis of Weber-Christian type.

After surgery, serous material continued to exude from the sites of his incisions; he was weak, tired, and suffered from malaise. He was given 5 mg of dexamethasone every six hours intravenously, but one week later similar new skin lesions began developing in his perianal region and right loin, as well as sharp constant upper abdominal pains with central and upper abdominal rebound, tenderness, and guarding. Abdominal roentgenogram revealed an ileus with considerable gas and fluid levels within his small bowel. For this reason, 200 mg daily of cyclophosphamide was added to his immunosuppressive regimen. Slowly but gradually his condition began to improve and he was able to be discharged from the hospital three weeks later receiving 6 mg of oral dexamethasone daily and 200 mg of oral cyclophosphamide daily. There had been marked improvement of his skin lesions and his constitutional symptoms had subsided. After nine months, cyclophosphamide therapy was stopped and one year after this, dexamethasone therapy was also withdrawn. During the next two years he remained well without treatment except for two minor exacerbations of his skin lesions, in each case precipitated by local trauma.

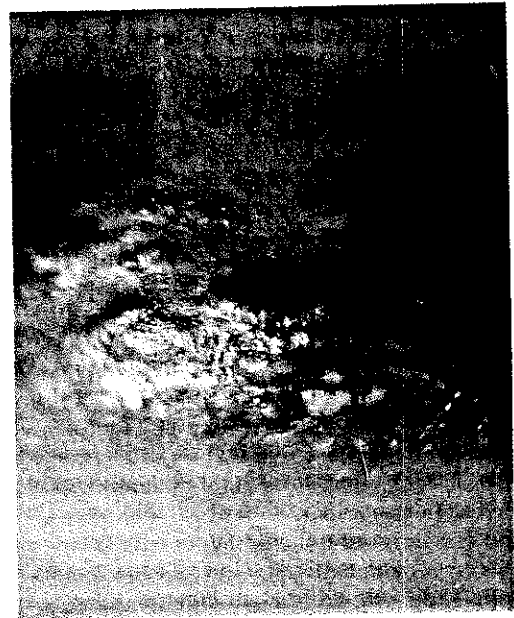
Accepted for publication May 17, 1982.

From the Department of Immunology, St Vincent's Hospital and the Department of Medicine, University of South Wales, Sydney (Drs Breit and Penny, Mr Robinson, and Ms Luckhurst), The Institute of Clinical Pathology and Medical Research, Westmead (Dr Clark), and the Department of Clinical Immunology, Royal Perth Hospital, Perth (Dr Dawkins), Australia.

Reprint requests to Department of Immunology, St Vincent's Hospital, Victoria Street, Darlinghurst NSW 2010, Australia (Dr Breit).



Fig 1.—Left, Lower abdominal and genital lesions of first patient demonstrates multiple areas of erythema and suppuration. Right, Close-up view shows similar lesion in second patient.



CASE 2.—Large, painful erythematous skin lesions began to develop in March 1979, in the 36-year-old brother of the first patient. He was otherwise well and receiving no medication but like his brother, over the years, similar isolated lesions developed often precipitated by trauma. On previous occasions when these had been incised, clear serous sterile fluid had been obtained. On this occasion, lesions appeared spontaneously over his left shoulder, left lumbar region, and left groin. By May 1979, similar lesions had developed over the left side of the chest and upper arm. These had become red and had ruptured, spontaneously discharging clear fluid. They did not respond to treatment for one week with 50 mg of oral prednisone daily and he was then admitted to the Royal Perth (Western Australia) Hospital. Examination revealed multiple large tender subcutaneous swellings involving the whole lumbar region and extending to the left iliac fossa, and the left groin, and into the scrotum and penis. He also had a large indurated erythematous area over his left deltoid region that had ruptured to discharge clear fluid (Fig 1, right). The rest of the results of his physical examination were normal. A diagnosis of Weber-Christian disease was made.

Findings for complete blood cell count, ESR, serum urea nitrogen, creatinine, serum electrolytes, albumin, total protein, liver function tests, amylase, urinalysis, and immunoglobulin and complement levels were all normal. No antinuclear antibodies or cryoproteins were detected. Serum electrophoresis revealed a low α_1 -globulin level and serum levels of α_1 -AT were found to be 0.25 g/L (normal, 2 to 4 g/L). His condition was diagnosed as severe α_1 -AT deficiency with phenotype PiZZ as part of the family study of case 1, initially conducted in 1976. Chest roentgenogram showed basal bullous changes and a left pleural effusion that was thought to be related to systemic involvement with Weber-Christian disease. Biopsy specimens of his skin lesions showed perivascular lymphoid infiltration in the reticular dermis and some suppuration in the subcutis. There was insufficient adipose tissue on biopsy specimens to confidently substantiate the presence of panniculitis.

While in the hospital he remained febrile with pleuritic chest pain and some dyspnea for seven days. In the hospital he received 0.5 mg of oral colchicine every eight hours for its anti-inflammatory action and 500 mg of cloxacillin every six hours as cultures of swabs from biopsy sites had yielded *Staphylococcus aureus* as well as *Proteus* and *Citrobacter* sp. After four to five days his condition

started to improve with gradual resolution of dyspnea and skin lesions over the next two weeks, when therapy was suspended and he was discharged from the hospital. Subsequently, he has had several similar small lesions arise both spontaneously and as a result of trauma. These lesions have only lasted about one week and have subsided spontaneously without discharging any material or requiring treatment.

METHODS

A number of immunological investigations were carried out on these two patients, as well as on another brother who was clinically well but also showing α_1 -AT deficiency, with a serum level of 0.28 g/L (normal, 2 to 4 g/L) and phenotype PiZZ. Three sex-matched medical students without α_1 -AT deficiency were used as controls. All subjects were well and receiving no medications at the time of study.

Serum Protein Determinations

Using standard radial immunodiffusion techniques, levels of the following serum proteins were determined: IgG, IgM, IgA, C1q, C3, C4, C5, factor B, C1 inhibitor, α_1 -AT, α_2 -macroglobulin, α_1 -antichymotrypsin, and inter- α -trypsin inhibitor. Functional assessment of the classic and alternative pathways of complement activation was undertaken by measuring the reciprocal of the titer of serum lysing 50% of sensitized sheep red cells (CH₅₀)⁸ and unsensitized rabbit erythrocytes (PH₅₀)⁹ respectively.

Skin Tests

In vivo assessment of delayed hypersensitivity (DTH) responses were carried out by intradermal injections of 0.1 mL of *Candida* (1:20 dilution), 5 units of streptokinase-streptodornase, and 10 units of PPD. Autologous serum and saline were administered as controls. The induration associated with all injections was read at 1, 4, 8, and 48 hours and recorded as the mean of the largest and smallest diameters of the lesions. A result greater than 0.5 cm was considered positive.

Lymphocyte Function

Serum samples from the three α_1 -AT-deficient subjects and three controls were obtained and either used fresh or stored at -70°C . These serum samples were used as a 20%

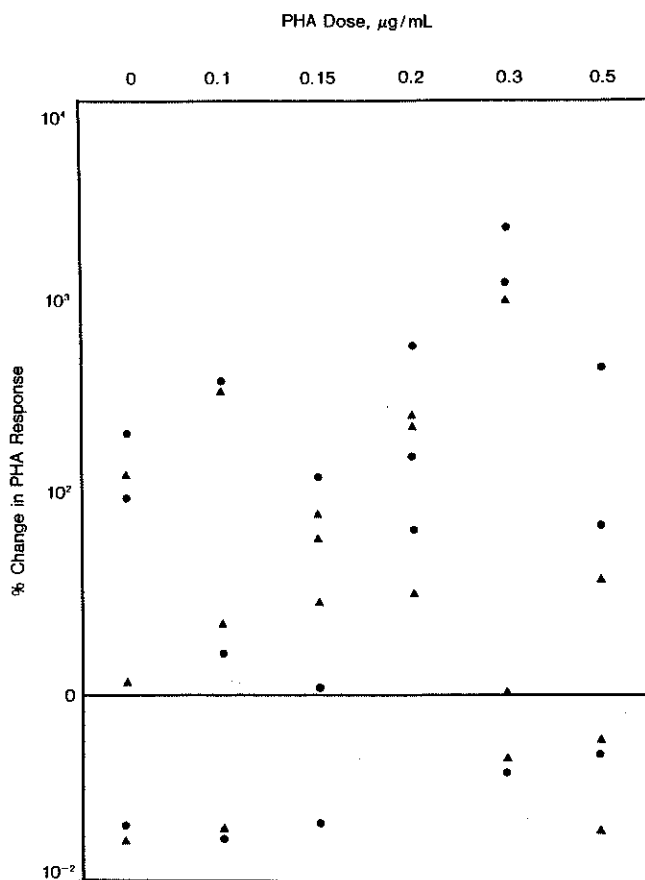


Fig 2.—Percentage change in phytohemagglutinin (PHA) response of patient (triangle) and control (circle) lymphocytes when each was cultured in patient serum compared with control serum. % change = $\{[(\text{response in patient serum}) - (\text{response in control serum})] / \text{response in control serum}\} \times 100 / 1$.

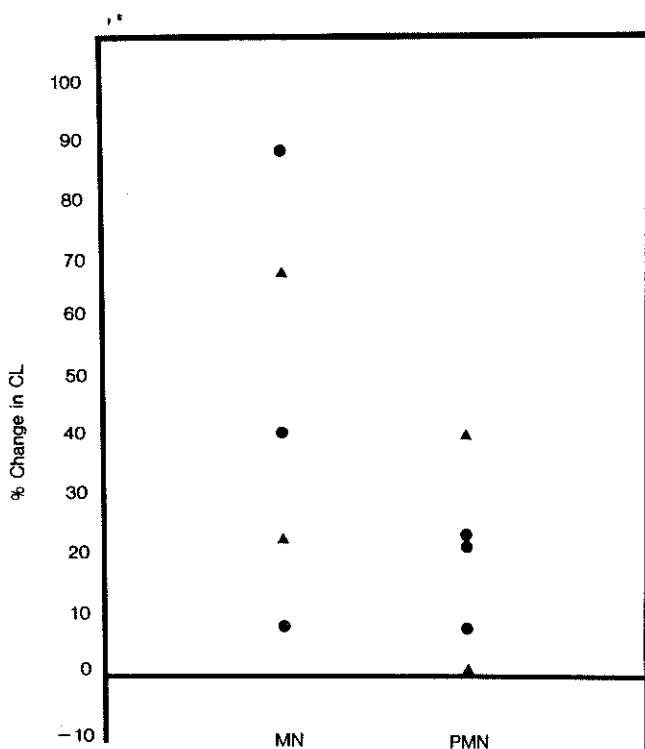


Fig 3.—Percentage change in chemiluminescence (CL) response of patient (triangle) and control (circle) monocytes (MN) and neutrophils (PMN) when each was activated in patient serum compared with control serum. % change = $\{[(\text{response in patient serum}) - (\text{response in control serum})] / \text{response in control serum}\} \times 100 / 1$.

supplement in determining the phytohemagglutinin (PHA) response of isolated peripheral blood mononuclear cells of all experimental subjects. The culture was carried out using a standard microculture technique¹⁰ on quadruplicate samples at PHA (purified PHA), concentrations of 0.1, 0.15, 0.2, 0.3, and 0.5 µg per mL of culture. At the end of three days' culture, the rate of DNA synthesis, measured by tritiated thymidine incorporation, was determined.

Neutrophil and Monocyte Function

Polymorphonuclear leukocyte (PMN) and monocyte function was assessed using the chemiluminescence technique essentially as previously described.¹¹ In brief, mononuclear cells (MNs) and PMNs were isolated from the peripheral blood of the three α_1 -AT-deficient subjects and three controls with the use of Ficoll-Hypaque density gradient centrifugation and dextran sedimentation. The MNs or PMNs (1×10^6 in 1 mL of Hanks' balanced salt solution) from each subject were placed in vials in the presence of 50 µL of 0.1% luminol, 2.2 mL phosphate-buffered saline, and 700 µL of the appropriate serum and counted in a liquid scintillation counter in the out of coincidence mode to obtain a baseline value. One milliliter of opsonized zymosan (50 mg/mL) was then added to activate the cells that were then counted every two minutes for six s. The peak response was obtained for each sample.

RESULTS

Serum Protein Determinations

All results, with the exception of reduced α_1 -AT levels, were within the normal ranges.

Skin Tests

There was no difference in the two groups in terms of the number of positive DTH responses or their magnitudes. There was, however, a difference in their time course. Of the five positive responses in the patient group at 48 hours, four were positive by eight hours. By contrast, none of the positive responses in the control group were detectable by eight hours. It is unlikely that these were nonspecific responses, as no reaction was seen with injection of autologous serum or saline. In addition, the eight-hour response was only seen in skin test sites that were subsequently positive at 48 hours.

Lymphocyte Function

At most of the low and intermediate doses of PHA, the lymphocyte proliferative response was considerably greater in the presence of the patient's serum than in the presence of the corresponding control serum. This difference was not seen in control cultures without PHA. Of those responses that were greater in control serum, most were contributed by the brother with no antecedent illnesses (Fig 2).

PMN and MN Function

In every instance the chemiluminescence responses of MNs and PMNs were greater in the

presence of patient than control serum samples, with mean percentage increases of 45% and 18%, respectively (Fig 3).

COMMENT

Weber-Christian disease is a rare clinical syndrome characterized by the appearance of recurrent multiple subcutaneous nodules often accompanied by fever.^{12,13} Histological examination shows necrosis of subcutaneous adipose tissue. Systemic involvement may occur with inflammation of adipose tissue in or around any internal organ. If this occurs, the disorder is associated with a high mortality; and no treatment has been found to be consistently satisfactory. Its origin is not known and only one previous study¹⁴ has examined immunologic factors. In a single patient, decreased cell-mediated immunity and increased immunoglobulin levels were found. The patient however, was studied while receiving corticosteroid therapy and was very ill in the hospital and hence these findings are difficult to interpret.

Although adequate histological specimens are not available in our second case, when the total clinical picture is considered, these two brothers undoubtedly had systemic Weber-Christian disease. Although *S aureus* was isolated from the serous discharge from a biopsy site of patient 2, it is most unlikely to have been involved in the pathogenesis of his lesions and is much more likely to reflect secondary infection.

α_1 -Antitrypsin is a plasma serine protease inhibitor for which there are more than 26 different alleles, each designated by letters of the alphabet. In any individual, two of these combine to determine the α_1 -AT phenotype. M is the most common allele and is associated with normal α_1 -AT levels of 2 to 4 g/L. Some alleles, such as S (58% of normal) and Z (16% of normal), are associated with a reduction in plasma α_1 -AT levels, which may only be moderate in a heterozygote, such as PiMS or PiMZ, or marked in a homozygous individual, such as PiZZ. Phenotyping for these different alleles is carried out by electrophoretic techniques that are independent of the plasma level, the latter being quite unreliable in differentiating various phenotypes.

The occurrence of α_1 -AT deficiency with Weber-Christian disease has been reported twice previously^{15,16} but no immunologic studies were undertaken in these cases. The presence of this disease in two brothers with severe α_1 -AT deficiency makes it highly unlikely that this association is purely by chance. The youngest brother with severe α_1 -AT deficiency may be at increased risk of having Weber-Christian disease develop in later years. Like most genetic risk factors, α_1 -AT deficiency probably has a complex relationship to the development of Weber-Christian disease, and factors including other genetic markers and an appropriate environmental stimulus are also likely to be required.

While the origin and pathogenesis of Weber-Christian disease are not understood, there is no doubt that the basic lesions are inflammatory in nature¹³ with consequent participation of phagocytic cells and inflammatory mediators. Although there is

no direct evidence for it, they may be vasculitic in nature.¹⁷ If this were so, lymphoid cell function and antibody synthesis would be of great importance. Proteases play a key role in the function of all of these systems; and as α_1 -AT is the most important plasma protease inhibitor, it would not be surprising if its absence led to abnormalities in the regulation of inflammatory and immunologic reactions. We have examined each of the systems that might conceivably be relevant in the pathogenesis of Weber-Christian disease to ascertain whether there was any influence exerted by α_1 -AT.

The DTH response is a very useful in vivo index not only of cell-mediated immunity, but also of the many cells and mediators involved in the subsequent inflammatory response. The considerable acceleration in the time course of this reaction in the α_1 -AT-deficient subjects suggests that there might be a hyperreactive inflammatory response predisposing to Weber-Christian disease.

T lymphocytes are important regulatory cells and abnormalities in their function are thought to underlie a large number of immunologic disorders. Subpopulations of T lymphocytes not only regulate cell-mediated responses but antibody synthesis by B lymphocytes. If Weber-Christian disease has as its basis a vasculitis, regulation of antibody and lymphokine synthesis is likely to be of great importance. Using the PHA response, a widely accepted index of T-cell function, we have demonstrated that lymphocyte responsiveness is enhanced in the presence of patient serum samples (Fig 1). This was observed at low and intermediate doses of PHA. The mechanism of action of α_1 -AT is probably via inhibition of membrane-bound serine proteases, thought to be involved in the activation of lymphocytes.¹⁷⁻²⁰ Proteases themselves may also be mitogenic to lymphocytes^{21,22} and α_1 -AT may act by inhibiting the activity of these extracellular proteases that are present in abundance in serum and tissues at sites of inflammation. α_1 -Antitrypsin has also been detected on the surface of concanavalin A-stimulated human lymphocytes but not on unstimulated cells,²³ suggesting its attachment to membrane-bound enzymes and further implicating it in the activation of T cells. In vivo, α_1 -AT may help to limit lymphocyte activation in inflammatory disease. Conversely, a decrease in α_1 -AT levels and loss of acute-phase reactant properties as is seen with some α_1 -AT phenotypes such as PiZZ could be expected to lead to exaggerated lymphocyte responses and possible abnormalities in immunoregulation.

There is no doubt that the major lesion of Weber-Christian disease is inflammatory in nature. In such lesions, irrespective of the initiating event, the tissue damage is usually characterized by large accumulations of PMNs and MNs. In addition, macrophages have an important role in antigen processing and manifestation of T cells. Enhanced activation of these cells, such as we have demonstrated in the presence of α_1 -AT-deficient serum (Fig 3), could well result in increased tissue injury. Because of its low molecular weight, α_1 -AT can easily enter tissue spaces and this, coupled with its acute-phase reac-

tant properties, suggests that it may be one of the important proteins regulating phagocytic cell function at sites of inflammation. The mechanism of inhibition of PMN and MN activation by α_1 -AT is probably through inactivation of membrane-bound serine esterases known to be involved in the activation of phagocytes.^{24,28} There is also evidence that α_1 -AT may influence the function of phagocytic cells by its interaction with C3,^{29,30} an important opsonic protein.

We have demonstrated enhanced activation of lymphocytes, MNs and PMNs, as well as accelerated DTH, in these three subjects with severe α_1 -AT deficiency, two of whom also had Weber-Christian disease. There appeared to be no major differences in the hyperreactivity exhibited by the subjects suggesting that it was due to the α_1 -AT deficiency and that other genetic and environmental factors must also be important in the pathogenesis of Weber-Christian disease. It is not surprising that α_1 -AT-deficient subjects are predisposed to the development of inflammatory diseases since proteases play

a fundamental role in the regulation of immunologic and inflammatory responses that mediate tissue injury in disorders such as Weber-Christian disease. They accomplish this by the regulation of cell function and the activation of inflammatory mediators such as complement and kinin systems, coagulation and fibrinolysis.³¹ α_1 -Antitrypsin is present in the highest molar concentrations of any of the protease inhibitors and has a very wide range of activity against a large number of enzymes, including leukocytic neutral proteases, collagenase, elastase, trypsin, thrombin, and kallikrein.³¹ Patients with α_1 -AT deficiency may therefore have a decreased capacity to regulate these enzymes because of a decrease both in serum levels and acute-phase responsiveness of the protein, leading to a general exaggeration of immunologic and inflammatory responses in Weber-Christian disease.

V. F. Munro, FRCPA, J. A. Milne, and M. C. Mihm made assessments of biopsy specimens and J. Ziegler, FRACP, and J. Charlesworth, MD, provided assistance with complement assays. Helen Blake and Claire Molenaar provided technical help.

References

- Cox DW, Huber O: Rheumatoid arthritis and α_1 -antitrypsin. *Lancet* 1976;1:1216-1217.
- Buisseret PD, Pembrey ME, Lessof MH: α_1 -Antitrypsin phenotypes in rheumatoid arthritis and ankylosing spondylitis. *Lancet* 1977;2:1358-1359.
- Breit SN, Clark P, Penny R: α_1 -Protease inhibitor (α_1 -antitrypsin) phenotypes in rheumatic diseases, abstracted. *Aust NZ J Med* 1980;10:271.
- Arnaud P, Galbraith RM, Faulk WP, et al: Increased frequency of the MZ phenotype of α_1 -protease inhibitor in juvenile chronic polyarthritis. *J Clin Invest* 1977;60:1442-1444.
- Arnaud P, Chapuis-Cellier C, Souillet G, et al: High frequency of deficient Pi phenotypes of α_1 -antitrypsin in nonatopic infantile asthma. *Trans Assoc Am Physicians* 1976;89:205-214.
- Geddes DM, Webley M, Brewerton DA, et al: α_1 -Antitrypsin phenotypes in fibrosing alveolitis and rheumatoid arthritis. *Lancet* 1977;2:1049-1050.
- Brewerton DA, Webley M, Murphy AH, et al: The α_1 -antitrypsin phenotype MZ in acute anterior uveitis. *Lancet* 1978;1:1103.
- Gewurz H, Svyehira LA: Complement, in Rose NR, Friedman H (eds): *Manual of Clinical Immunology*. American Society for Microbiology, 1976, pp 36-47.
- Platts-Mills TAE, Ishizaka K: Activation of the alternate pathway of human complement by rabbit cells. *J Immunol* 1974;133:348-358.
- Oppenheim JJ, Schechter B: Lymphocyte transformation, in Rose NR, Friedman H (eds): *Manual of Clinical Immunology*. American Society for Microbiology, 1976, pp 81-94.
- Robinson JP, Penny R: Chemiluminescent response in normal human phagocytes: I. Automated measurements using a standard liquid scintillation counter. *J Lab Clin Immunol* 1982;7:215-217.
- MacDonald A, Feiweil M: A review of the concept of Weber-Christian panniculitis with a report of five cases. *Br J Dermatol* 1968;80:355-361.
- Milner RDG, Mitchinson MJ: Systemic Weber-Christian disease. *J Clin Pathol* 1965;18:150-156.
- Kaneko F, Shunsuke I, Nagai M: A case of Weber-Christian disease suggesting cellular immunodeficiency. *J Dermatol* 1975;2:137-141.
- Warter J, Storck D, Grosshans E, et al: Syndrome de Weber-Christian associe à un deficit en α_1 -antitrypsine. *Ann Med Interne* 1972;123:877-882.
- Rubinstein HM, Joffer AM, Kudrna JC, et al: α_1 -Antitrypsin deficiency with severe panniculitis. *Ann Intern Med* 1977;86:742-744.
- Bata J, Deviller P, Colobert L: Inhibition de la biosynthèse du DNA chez les lymphocytes humains par l'effet de la α_1 -antitrypsine. *C R Acad Sci P* 1977;285:1499-1501.
- Arora PK, Miller HC, Aronson LD: α_1 -Antitrypsin is an effector of immunologic stasis. *Nature* 1977;274:589-590.
- Vischer TL: Protease inhibitors reduce mitogen induced lymphocyte stimulation. *Immunology* 1979;36:811-813.
- Fulton RJ, Hart DA: Detection and partial characterization of lymphoid cell surface proteases. *Cell Immunol* 1980;55:394-405.
- Kaplan JG, Bona C: Proteases as mitogens. *Exp Cell Res* 1974;88:388-394.
- Vischer TL, Bretz U, Baggolini M: In vitro stimulation of lymphocytes by neutral proteases from human polymorphonuclear leukocyte granules. *J Exp Med* 1976;144:863-871.
- Lipsky JJ, Berninger RW, Hyman LR, et al: Presence of α_1 -antitrypsin on mitogen-stimulated human lymphocytes. *J Immunol* 1979;122:24-26.
- Kitagawa S, Takaku F, Sakamoto S: Serine protease inhibitors inhibit superoxide production by human polymorphonuclear leukocytes and monocytes stimulated by various surface active agents. *FEBS Lett* 1979;107:331-334.
- Nagai K, Nakamura T, Koyama J: Characterization of macrophage proteases involved in the ingestion of antigen-antibody complexes by the use of protease inhibitors. *FEBS Lett* 1978;92:299-302.
- Goldstein BD, Witz G, Amoruso M, et al: Protease inhibitors antagonize the activation of polymorphonuclear leukocyte oxygen consumption. *Biochem Biophys Res Commun* 1979;88:854-860.
- Kitagawa S, Takaku F, Sakamoto S: Evidence that proteases are involved in superoxide production by human polymorphonuclear leukocytes and monocytes. *J Clin Invest* 1980;65:74-81.
- Musson RA, Becker EL: The role of an activatable esterase in immune dependent phagocytosis by human neutrophils. *J Immunol* 1977;118:1354-1364.
- Dierich MP, Landen B, Schmitt M: Complement receptor analogous factors in human serum: Isolation of a molecule inhibitory for complement-dependent rosette formation, its identification as α_1 -antitrypsin and its functional characterization. *Immunobiology* 1979;156:153-167.
- Mod A, Fust G, Gergely J, et al: Inhibition of C3-receptor-dependent phagocytosis by α_1 -antitrypsin, in Preud'Homme JL, Hawken VAL (eds): *Proceedings of the Fourth International Congress of Immunology, 1980*. New York, Academic Press Inc, 1980, theme 11, workshop 4, paper 30.
- Breit SN, Penny R: The role of α_1 -protease inhibitor (α_1 -antitrypsin) in the regulation of immunologic and inflammatory reactions. *Aust NZ J Med* 1980;10:449-453.

